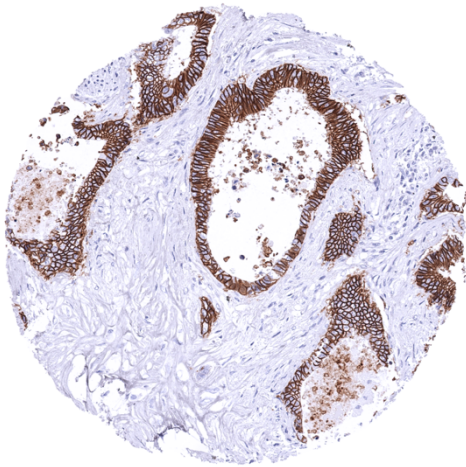


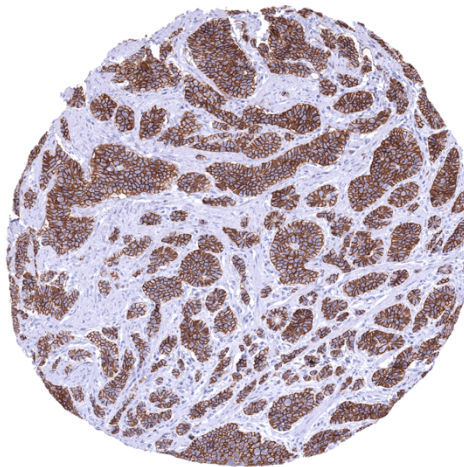
Anti- CDH17 Antibody MSVA-517M / Mouse monoclonal

Human SwissProt	Q12864
Human Gene Symbol	CDH17
Synonyms	BILL-cadherin; Cadherin-17; CDH17; HPT-1 cadherin; human intestinal peptide-associated transporter HPT-1; human peptide transporter 1 (HPT-1); Intestinal peptide-associated transporter HPT-1; LI-cadherin (liver-intestine); Liver Cadherin; Liver-intestine cadherin
Specificity	CDH17
Immunogen	Recombinant human CDH17 fragment
Isotype	Mouse / IgG2b, kappa
Species Reactivity	Human


Localization	Cell Surface, Cytoplasmic
Storage & Stability	Antibody with azide – store at 2 to 8 C. Antibody without azide – store at -20 to -80 C. Antibody is stable for 24 months. Non-hazardous. No MSD required.
Supplied As	200ug/ml of Ab Purified from Bioreactor Concentrate by Protein A/G. Prepared in 10mM PBS with 0.05% BSA & 0.05% azide. Also available without BSA
Positive Control	Colon: A strong CDH17 staining should be seen in all epithelial cells.
Negative Control	Colon: Non-epithelial cells should not show any CDH17 immunostaining.



Colorectal adenocarcinoma showing strong CDH17 positivity of tumor cells.



Neuroendocrine tumor of the ileum with strong CDH17 immunostaining of all tumor cells.



Strong membranous CDH17 staining in all epithelial cells of the colon mucosa.

Biology

Cadherin-17 (CDH17) is an 92,2 kDa protein coded by the CDH17 gene on chromosome 8q22.1. As other members of the cadherin superfamily, CDH17 is a calcium-dependent, membrane-associated glycoprotein. CDH17 acts as an adhesion protein and has a role as a proton-dependent peptide transporter. CDH17 is involved in absorption of various peptide-based drugs. CDH17 was also suggested to be relevant for the morphological organization of liver and intestine. In cancer, aberrant CDH17 expression was found to be linked to unfavorable tumor features in several cancer entities. Among normal tissues, strong CDH17 staining occurs in all epithelial cells of small intestine, colorectum and appendix. Gallbladder epithelium exhibits a weak to moderate focal membranous staining while intrahepatic bile ducts are CDH17 negative. Few small intrapancreatic excretory ducts show a moderate to strong membranous CDH17 staining. In few cases a focal membranous staining can be seen in endometrium glands. Among tumors, CDH17 immunostaining occurs in a large fraction of adenocarcinomas derived from the colorectum, stomach, and the esophagus. Adenocarcinomas of the pancreas, mucinous ovarian cancers, cancers of the female genital tract, and other neoplasms can occasionally also express CDH17.

Potential Research Applications

- The diagnostic utility of CDH17 IHC should be investigated in a large cohort containing as many as possible tumors from as many as possible different entities.
- The clinical significance of CDH17 expression levels in gastrointestinal tumors deserves further investigation.

Protocol Suggestions

Dilution: 1:1800 ; pH 7,8 is optimal. Freshly cut sections should be used (more than 10 days between cutting and staining deteriorates staining intensity for most antibodies in IHC).

Limitations

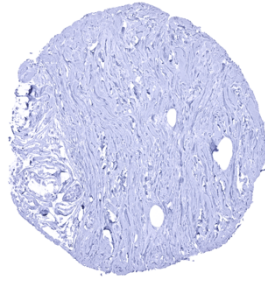
This antibody is available for **research use only** and is not approved for use in diagnostics.

Warranty

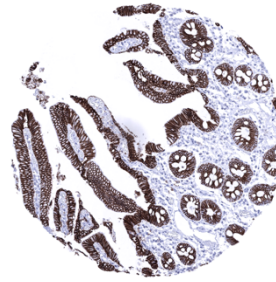
There are no warranties, expressed or implied, which extend beyond this description. MSVA is not liable for any personal injury or economic loss resulting from this product.



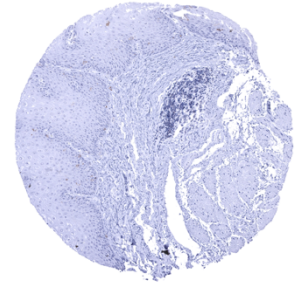
Appendix, mucosa - A strong membranous CDH17 staining occurs in all epithelial cells of the appendix mucosa



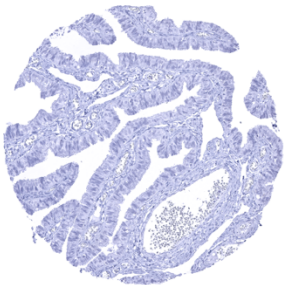
Breast



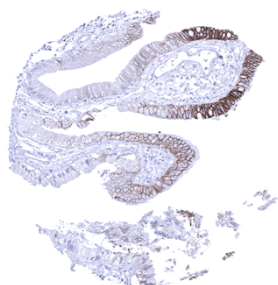
Duodenum, mucosa - A strong membranous CDH17 staining occurs in all epithelial cells of the duodenum mucosa



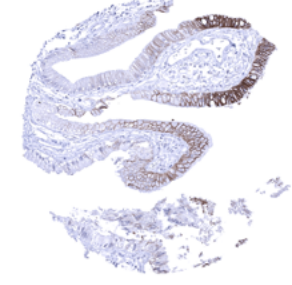
Esophagus, squamous epithelium



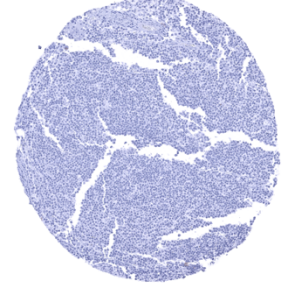
Fallopian tube, mucosa



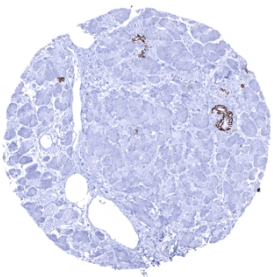
Gallbladder, epithelium - A membranous CDH17 staining can be seen in the gallbladder epithelium



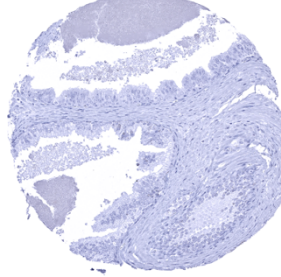
Ileum, mucosa - A strong membranous CDH17 staining occurs in all epithelial cells of the ileum mucosa



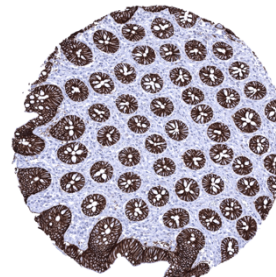
Lymph node



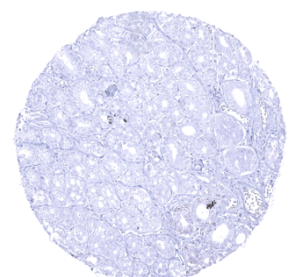
Pancreas - A strong membranous CDH17 staining can be seen in some small sized excretory ducts of the pancreas



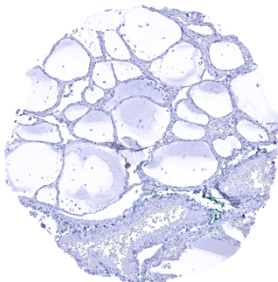
Prostate



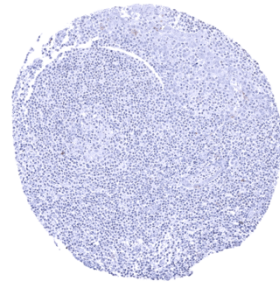
Rectum, mucosa - A strong membranous CDH17 staining occurs in all epithelial cells of the rectum mucosa



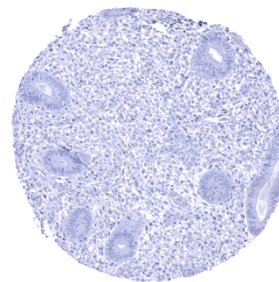
Stomach, antrum - CDH17 staining is largely absent in stomach glands



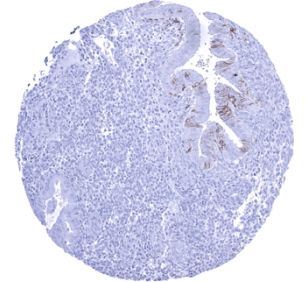
Thyroid gland



Tonsil



Uterus, endometrium (proliferation)



Uterus, endometrium (secretion) - Focal membranous CDH17 staining can occur in selected endometrial glands